

**Case Report**

Remission of Her2neu Amplified Breast Carcinoma Involving Brain and Leptomeninges with Concurrent Disappearance of Her2neu Amplified Circulating Tumor Cells Following Intrathecal and Systemic Delivery of Trastuzumab

Ian J Robertson¹, Timothy A Gregory², Monica E Loghin^{2*}¹Department of Internal Medicine, Walter Reed National Military Medical Center, Bethesda, MD, USA²Department of Neuro-Oncology, The University of Texas MD Anderson Cancer Center, Houston, TX, USA

***Corresponding author:** Monica E Loghin, Department of Neuro-Oncology, The University of Texas MD Anderson Cancer Center, 1400 Holcombe Blvd, Houston, TX, 77030, USA

Citation: Robertson IJ, Gregory TA, Loghin ME (2023) Remission of Her2neu Amplified Breast Carcinoma Involving Brain and Leptomeninges with Concurrent Disappearance of Her2neu Amplified Circulating Tumor Cells Following Intrathecal and Systemic Delivery of Trastuzumab. Ann Case Report. 8: 1331. DOI:10.29011/2574-7754.101331

Received: 26 May 2023, **Accepted:** 31 May 2023, **Published:** 02 June 2023

Abstract

Leptomeningeal disease (LMD) is known to have exceptionally poor prognosis with few viable treatment options in patients with cancer. HER2+ breast cancer in particular has a predilection for leptomeningeal dissemination relative to other primary malignancies. In this case report, we detail the treatment of a patient with aggressive HER2+ breast carcinoma with leptomeningeal metastases who had remarkable sustained clinical response to systemic and intrathecal (IT) trastuzumab, with correlative cytologic and molecular spinal fluid studies that showed eradication of disease after targeted molecular treatment. This case emphasizes the therapeutic value of IT trastuzumab in a patient with HER2+ breast cancer associated LMD and the need to further explore this specific treatment approach in this patient population for whom treatment options remain very limited.

Keywords: Trastuzumab; Leptomeningeal Disease; HER2+ breast cancer

Introduction

Leptomeningeal disease (LMD) is a rare and devastating complication of breast cancer occurring in less than 5% of breast cancers patients; it portends an unfavorable prognosis with median survival of approximately 4 months after diagnosis [1]. No clear treatment guidelines exist, although a combination of radiotherapy, systemic chemotherapy, and intrathecal chemotherapy is typically utilized, with intrathecal trastuzumab more recently being

recognized as a potential agent that can prolong survival in this patient population [2]. We present a case of a 52-year-old female with HER2+, ER-, PR- breast adenocarcinoma with progressive brain and leptomeningeal metastases who after treatment with systemic and intrathecal trastuzumab, in conjunction with radiotherapy and chemotherapy, sustained a durable clinical and radiologic remission of greater than a decade after initial treatment.

Case Presentation

A 52-year-old woman presented in December 2011 to the Neuro-oncology clinic for management of newly diagnosed leptomeningeal

disease. She was initially diagnosed with invasive ductal carcinoma of the left breast, estrogen receptor (ER) and progesterone receptor (PR) negative, and HER2neu positive in July 2005. She underwent bilateral mastectomy with left axillary dissection and the pathology staging confirmed a T2 N2 M0 tumor. She received adjuvant chemotherapy with doxorubicin and cyclophosphamide (AC) followed by paclitaxel and trastuzumab which she continued for one year in conjunction with radiation therapy (RT) to the left chest and axilla. She was disease free until October 2009 when she developed right sided neck pain and persistent headache. Subsequent brain MRI revealed 2 brain metastases, one in the right vermis and a second in the right cerebellar hemisphere adjacent to the tentorium and extending into the right occipital lobe. The patient underwent surgical resection of the right cerebellar tumor with pathology positive for metastatic adenocarcinoma with HER-2/neu gene amplification. Thereafter, she received stereotactic radiosurgery to both metastases. She then was initiated on dual chemotherapy with capecitabine and lapatinib for 6 cycles followed by single agent lapatinib for 4 cycles. One year later, in December 2010 the patient was found to have recurrent disease in the cerebellum for which she received 30 Gy palliative radiation. She was stable until 04/2011 when the brain MRI revealed a new metastasis in the left occipital lobe which was treated with gamma knife radiosurgery. Thereafter, she resumed chemotherapy with capecitabine and lapatinib. In late August 2011 she developed low back pain, pain in her right gluteus muscle, and perianal numbness which slowly progressed over the next 3-4 months with associated bowel and bladder dysfunction, at which time she was diagnosed with cauda equina syndrome. The PET/CT scan revealed multiple foci of increased uptake within the spinal canal at the lumbar spine and upper sacrum; the lumbo-sacral MRI revealed subarachnoid leptomeningeal lesions within the lower thoracic spine from T11 through L2 with patchy enhancement of nerve roots of the cauda equina (Figure 1). Cerebrospinal fluid (CSF) showed elevated protein of 515 MG/DL, 71 white blood cells and malignant cells consistent with metastatic adenocarcinoma originating from her primary breast malignancy. She completed 27 Gy radiation therapy and subsequently underwent an Ommaya reservoir placement in preparation for intrathecal (IT) therapy. In January 2012 she was initiated on IT trastuzumab 40 mg weekly and continued systemic treatment with capecitabine and lapatinib. After one cycle of treatment with 4 weekly doses of IT trastuzumab, the brain MRI revealed more obvious nodular enhancement coating the right lateral pons worrisome for tumor progression. Clinically the patient was improving with no back pain, less tightness in the right thigh and less perianal numbness. Repeat CSF cytology revealed only rare atypical cells with normal white cell number and minimally elevated protein (Figure 2). Her IT trastuzumab dose was increased to 80 mg weekly and IT topotecan 0.4 mg was added. Her systemic chemotherapy was changed to trastuzumab and vinorelbine.

Between 02/2012 and 10/2019 the patient received IT trastuzumab 100 mg and topotecan 0.4 mg every 4 weeks with durable clinical, radiographic, and CSF cytologic response with no adverse effects from the IT chemotherapy. The PET/CT scan from 3/09/2012 demonstrated that the nodular hypermetabolism in the spinal canal and surrounding the sacral roots had completely resolved. Concurrently, the spine MRI revealed significant improvement of the leptomeningeal disease, and follow up spine MRIs showed no evidence of disease (Figure 1). Her systemic treatment included trastuzumab and vinorelbine from early 2012 until December 2013, followed by single agent trastuzumab until 2014, conjugated trastuzumab-emtansine from 2014 to 2018 and trastuzumab and pertuzumab from 2014-2019. In August 2017 brain MRI revealed progression of the right cerebellar metastasis and the patient received a Laser interstitial Thermal therapy (LITT) therapy. A second LITT procedure was performed in November 2018 for recurrent disease in the right cerebellum. In October 2019 CSF cytology revealed malignant cells and IT topotecan was switched to cytarabine with consistent negative CSF cytology to date. Her systemic therapy was switched to tucatinib from 2019 to 2021 and since 2021 the patient has been receiving trastuzumab-deruxtecan.

PET/SCAN and MRI before and after Intrathecal therapy showing complete resolution of breast cancer

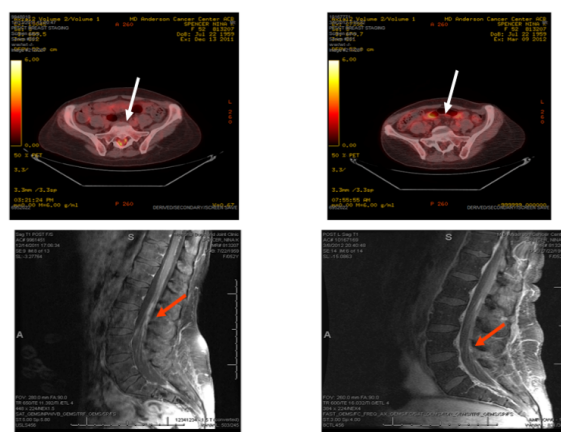


Figure 1: Top panel: Left, FDG PET/CT Multiple foci of increased up-take within the spinal canal at the lumbar spine and upper sacrum.. Right: FDG PET/CT Complete resolution of the leptomeningeal hypermetabolic in spinal canal. Bottom panel, Left, a Lumbo-sacral spine MRI12/14/11, before and after (Right lower panel) Lumbo-sacral spine MRI therapy.

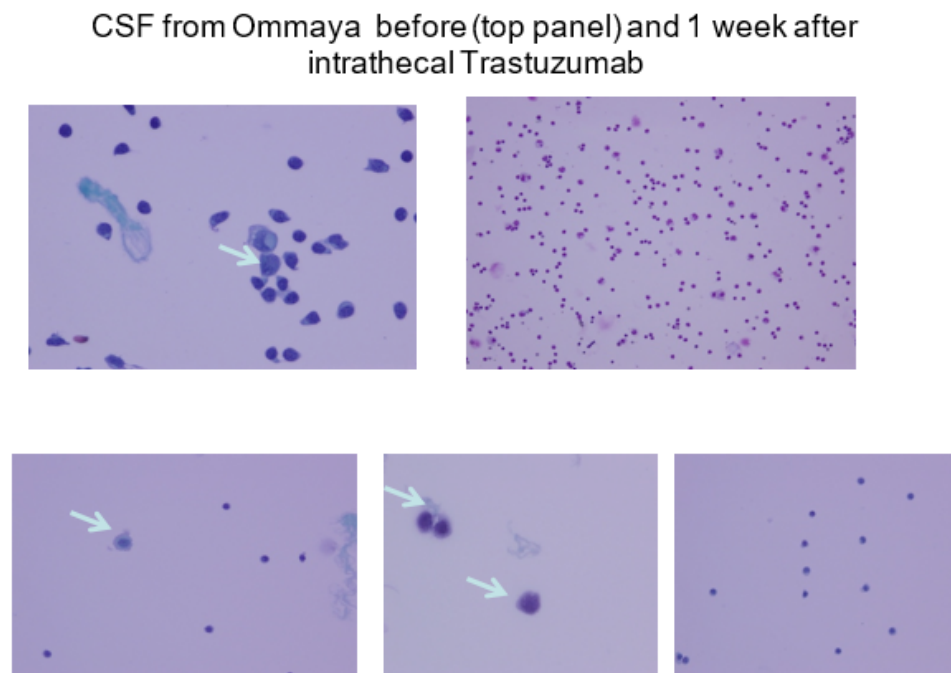


Figure 2: Top Panel demonstrates CSF findings with numerous malignant cells pre-treatment as compared to rare atypical cells post-IT Trastuzumab.

Over-expression and amplification of Her2neu by FISH in cerebellar tumor and in breast cancer cells in CSF

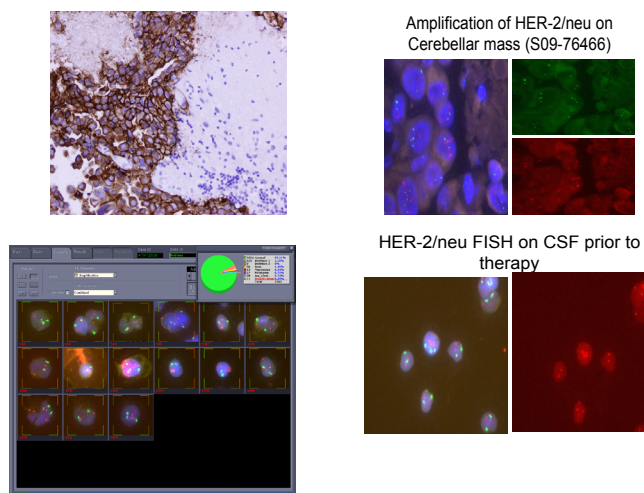


Figure 3: 3a (Top left): Cerebellum showing 4+ positive staining for Her2neu protein. 3b (Top Right): Corresponding section to 3a showed amplification of Her2neu gene compared to centromeric 17, DNA FISH for Her2neu on interphase nuclei, 3c (Bottom Left): Cells from CSF demonstrating amplification of Her2neu (red signal), compared to centromeric 17 (green signal), screen images (Bioview Duet). 3d (Bottom Right): Cells from CSF (Green signal centromeric 17), shows diploid signal compared to clustered red signals, consistent with gene amplification.

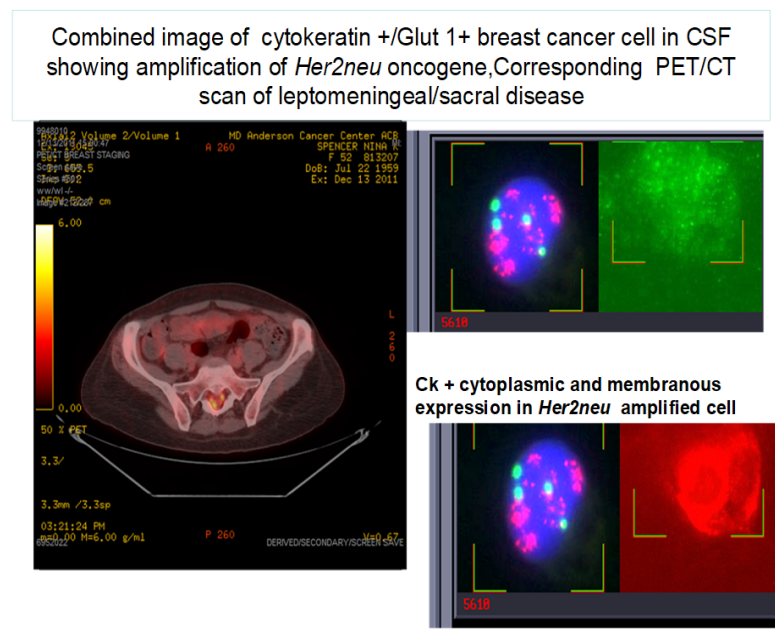


Figure 4: CSF cells showed strong membranous and cytoplasmic staining for GLUT1 (a glucose transporter protein that correlates with FDG uptake in metabolically active cells) with co-expression of cytokeratin and simultaneous amplification for Her2neu, which was demonstrated in ten cancer cells

Hercept-FITC assay: Membranous staining for Herceptin conjugated with FITC on malignant breast cancer cells in CSF baseline (left panel) and macrophages with phagocytosed Herceptin positive debris following therapy (right panel)

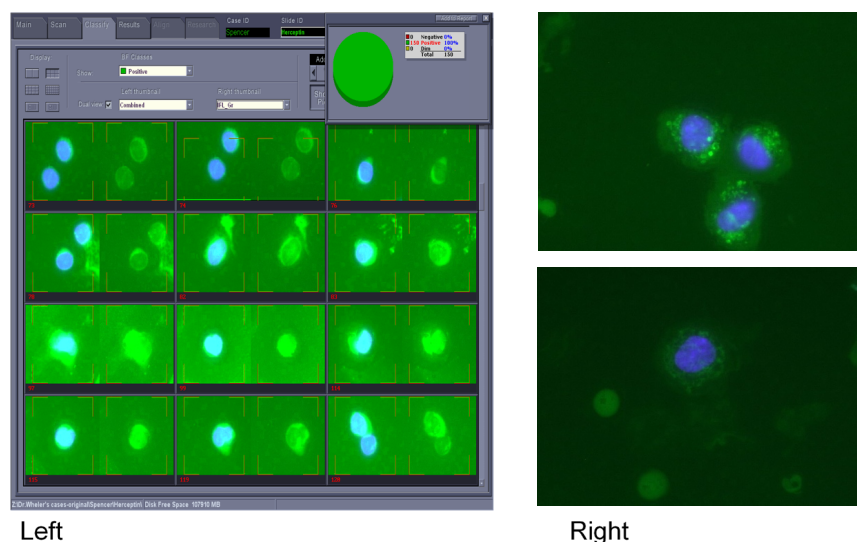


Figure 5: Image on left demonstrates the positive membranous staining for Herceptin using Flurescein isothiocyanate (FITC) antibody conjugation. The image on right demonstrates macrophage phagocytosis of Herceptin-positive debris 5 weeks following initiation of IT Trastuzumab.

Clinical status

Over the last 3-4 years, the patient has developed progressive bilateral spasticity of her lower extremities, left>right, gait ataxia, and has required a cane. She continues with chronic bowel and bladder dysfunction and mild saddle anesthesia.

Correlative Pathology, Cytology and Molecular studies

Our patient developed leptomeningeal metastases secondary to HER2+ invasive ductal breast carcinoma (IDC), which as compared to triple-negative breast cancer is associated with greater likelihood of CNS metastases, but also longer survival in cases of LMD [3,4]. Her2neu gene amplification was confirmed by analysis of cerebellar resection from 2009 demonstrating 4+ strong reactivity by immunohistochemistry for Her2neu and interphase FISH for Her2neu showing 20-30 copies of HER2neu gene compared to 4 copies of centromeric 17 (Figure 3a,b) (cut off values ratio copy number Her2neu gene: centromeric 17 = >2.2 (ref). EGFR amplification was also identified by FISH performed on the cerebellar tissue which is significant in that Her2 and EGFR co-amplification has been associated with shorter disease free survival and overall survival in patients with invasive ductal carcinoma [5]. CSF samples later obtained on 1/12/2012 from both lumbar puncture and as well as the Ommaya reservoir, prior to beginning trastuzumab, also showed a few carcinoma cells on cytology consistent with leptomeningeal metastases secondary to IDC. Concurrent CSF sample demonstrated highly atypical cells with amplification of Her2neu in 15/3763 (0.4%) and gains of Her2neu in 56/3763 (1.48%) (Figure 3c,d). An additional 40/3763 (1.1)% cells showed further genetic abnormalities either polysomy or monosomy of Her2neu, while a concurrent peripheral blood sample displayed similar amplification of Her2neu, as well as gains, monosomies and polysomies in the mononuclear cells consistent with circulating tumor cells. Similar to the EGFR expression in the previously resected cerebellar tumor, both the CSF cells as well as CTCs in the peripheral blood showed identical deletions of chromosome 7, resulting in monosomy of centromeric 7 and EGFR. In addition, CSF cells showed strong membranous and cytoplasmic staining for GLUT1 (a glucose transporter protein that correlates with FDG uptake in metabolically active cells) with co-expression of cytokeratin and simultaneous amplification for Her2neu, which was demonstrated in ten cancer cells (Figure 4). These findings were consistent with the PET avid leptomeningeal PET/CT scan. A similar phenomenon was demonstrated in the peripheral blood obtained at baseline; namely there were peripheral blood mononuclear cells (PBMN) demonstrating amplification of Her2neu by FISH with simultaneous demonstration of overexpression of GLUT1. PBMN cells were also assayed for amplification of Her2neu and was present in peripheral blood mononuclear cells.

Trastuzumab studies

We demonstrated that the malignant cells in the baseline CSF, prior to IT therapy showed strong membranous reactivity with fluoresced trastuzumab, which was verified with positive and negative controls. On 2/20/2012, (just over 5 weeks since initiation of IT trastuzumab), histiocytes within the CSF showed marked intra-cytoplasmic phagocytosis of debris that was positive for trastuzumab, consistent with antibody-dependent cytotoxicity mediated through the effect of trastuzumab reacting with the Her2neu receptor on the membrane of the breast cancer cells and causing the cancer cells to undergo apoptosis (Figure 5). Over time, following trastuzumab intra-theal therapy, we demonstrated disappearance of Her2neu amplified cells from the CSF until there was complete clearance by cytology on 3/19/2012. During IT therapy, CSF specimens showed degeneration of the malignant cells and a brisk lymphohistiocytic pleocytosis.

Longitudinal CSF and peripheral blood studies

In conjunction with the IT and systemic trastuzumab and chemotherapy, serial CSF samples obtained from her Ommaya reservoir have been negative for malignant cells since 3/19/2012 which correlated well with her concurrent MRI brain and spine studies that showed disappearance of her lesions. In addition her CTCs over time showed resolution of Her2neu amplification.

Discussion

Historically, women with leptomeningeal involvement by metastatic breast cancer have a dismal prognosis with mean survival times around 15 weeks following clinical presentation. HER2+ breast cancers, as well as triple-negative breast cancer, in particular, have a predilection for metastasis to the CNS; one study demonstrated that in 100 breast cancer patients with LMD, 46% were HER2+ and 22% were TNBC6. Lobular, as compared to ductal breast carcinoma, has also been demonstrated to have a greater predilection for LMD [7]. A combination of craniospinal irradiation, systemic therapy, and intrathecal chemotherapy have been demonstrated to be superior to any of these individual treatments in prolonging survival; albeit to a limited degree [8]. Although there is no clear consensus on specific therapeutic components associated with prolonged survival, the use of targeted therapies based on hormone receptor status has been shown to prolong survival, especially for tumors which convert receptor status during course of treatment or progression of disease [9]. Intrathecal therapies have most often consisted of cytarabine, thiopenta, and methotrexate [10], although in the last decade it has been growing evidence in the literature of case reports, retrospective and prospective trials supporting the efficacy of intrathecal trastuzumab in leptomeningeal disease. A meta-analysis of 24 studies encompassing 58 patients with HER2+ breast cancer

and LM treated with intrathecal trastuzumab showed an OS of 13.7 months, thus suggesting that anti-HER2 intrathecal therapy may confer a survival benefit relative to alternate regimens [11]. Another more recent Phase II study demonstrated more modest OS of 7.9 months in a cohort of 19 HER2+ breast carcinoma patients treated with weekly administrations of 150 mg of IT trastuzumab [12]. In particular, the EANO-ESMO group developed recent 2021 guidelines regarding differentiation of prognostic outcome in solid tumors with LMD based on stratification into 2 primary subtypes, Type I and Type II. The group defines Type I as confirmed LMD based on either cytologic or histologic findings versus probable LMD, defined by equivocal or negative CSF findings despite suggestive imaging or clinical symptoms. In their retrospective analysis, Type I disease was associated with overall decreased survival; specifically, 2.5 vs. 4.5 months in breast cancer. Furthermore, administration of either IT or systemic chemotherapy was found to improve survival outcomes in Type I but not Type II LMD, a finding consistent with the clinical outcome of our patient with confirmed (Type I) LMD [13]. Intrathecal trastuzumab seemed to be attractive in our case, in which there was no clear evidence of systemic metastatic disease outside of the CNS. The disappearance of the cancer cells in the spinal fluid, as well as the eventual clearance of circulating tumor cells in her peripheral blood, is presumed to have been mediated through the effect of the trastuzumab and Her2neu receptor induced apoptotic reaction, as demonstrated by subsequent CSF samples showing histiocytes with engulfed debris that were trastuzumab FITC positive. By using a novel in vitro assay for trastuzumab, which demonstrated this strong cellular response, we were able to predict that treating our patient with trastuzumab by an intra-theal route might well result in a successful outcome. Trastuzumab was also later added in order to treat her systemic disease as we noted that she had numerous circulating tumor cells (CTCs) that evidenced Her2neu amplification. Compared to her baseline there was a marked reduction in these amplified CTCs over time in both CSF and peripheral blood counts. The cancer reseeding theory [14] implicates a constant flux of malignant cells from a neoplasm through the blood stream and back to the original mass. Thus our findings of malignant cells in the cerebellar tumor, blood and CSF with similar molecular phenotypes, namely amplification for Her2neu, and deletions of chromosome 7, leading to monosomy or one copy of EGFR is to be expected. In conclusion we present a patient with stage IV ductal adenocarcinoma of the breast and leptomeningeal disease with concomitant brain metastases, who had demonstrable Her2neu amplified cancer cells in CSF and blood, and who had a dramatic and sustained clinical, cytological and molecular response of more than 10 years by using an “intense” and “personalized” treatment approach with a combination of intrathecal trastuzumab and systemic anti-HER2 therapies. It is important to highlight that in our case there was no evidence of active systemic disease, in contrast with the majority of HER2

positive breast cancer patients, and there was low burden of CNS metastatic disease. This treatment approach may reach long-term disease control with a low toxicity profile and preservation of quality of life.

Conclusions

Our case provides a clinical example, as well as mechanistic basis, for the potential of IT Trastuzumab in HER2+ LMD. We anticipate that the prolonged survival demonstrated in this patient case and promising early phase I/II studies will expand its use as first-line option in this patient population and ultimately improve survival outcomes.

Disclosures: None

Author Contributions: Manuscript writing and editing performed by I.R., T.G, and M.L. Supervision and clinical expertise provided by both T.G. and M.L. Details of clinical case and patient consent provided by M.L.

Funding Support: This research received no external funding.

Patient Consent: Obtained.

Data Availability Statement: Data supporting the study results can be provided followed by request sent to the corresponding author’s e-mail.

Conflicts of Interest: None.

References

1. Garcia-Alvarez A, Papakonstantinou A, Oliveira M (2021) Brain Metastases in HER2-Positive Breast Cancer: Current and Novel Treatment Strategies. *Cancers (Basel)*. 13: 2927.
2. Katayama MY, Ohgino K, Tamura R (2022) Leptomeningeal Metastases and Intrathecal Chemotherapy. *DMHT*. 2022: 1-23.
3. Leone JP, Leone BA (2015) Breast cancer brain metastases: the last frontier. *Exp Hematol Oncol*. 4: 33.
4. Brosnan EM, Anders CK (2018) Understanding patterns of brain metastasis in breast cancer and designing rational therapeutic strategies. *Ann Transl Med*. 6: 163.
5. Guo P, Pu T, Chen S, Qiu Y, Zhong X, et al (2017) Breast cancers with EGFR and HER2 co-amplification favor distant metastasis and poor clinical outcome. *Oncol Lett*.
6. Yust-Katz S, Garcíarena P, Liu D, Yuan Y, Ibrahim N, et al (2013) Breast cancer and leptomeningeal disease (LMD): hormone receptor status influences time to development of LMD and survival from LMD diagnosis. *J Neurooncol*. 114: 229-235.
7. Katayama MY, Ohgino K, Tamura R (2022) Leptomeningeal Metastases and Intrathecal Chemotherapy. *DMHT*. 2022: 1-23.
8. Carausu M, Carton M, Darlix A, Pasquier D, Leheurteur M, et al (2021) Breast cancer patients treated with intrathecal therapy for leptomeningeal metastases in a large real-life database. *ESMO Open*. 6: 100150.

9. Zhao W, Sun L, Dong G, Wang X, Jia Y, et al (2021) Receptor conversion impacts outcomes of different molecular subtypes of primary breast cancer. *Ther Adv Med Oncol*. 13: 175883592110129.
10. Franzoi MA, Hortobagyi GN (2019) Leptomeningeal carcinomatosis in patients with breast cancer. *Crit Rev Oncol Hematol*. 135: 85-94.
11. Zagouri F, Zoumpourlis P, Le Rhun E, Bartsch R, Zografos E, et al (2020) Intrathecal administration of anti-HER2 treatment for the treatment of meningeal carcinomatosis in breast cancer: A metanalysis with meta-regression. *Cancer Treatment Reviews*. 88: 102046.
12. Oberkamp F, Gutierrez M, Trabelsi Grati O, Rhun EL, Tredan O, et al (2023) Phase II study of intrathecal administration of trastuzumab in patients with HER2-positive breast cancer with leptomeningeal metastasis. *Neuro Oncol*. 25: 365-374.
13. Le Rhun E, Devos P, Weller J, Seystahl K, Mo F, et al (2021) Prognostic validation and clinical implications of the EANO ESMO classification of leptomeningeal metastasis from solid tumors. *Neuro Oncol*. 23: 1100-1112.
14. Kim MY, Oskarsson T, Acharyya S, Nguyen DX, Zhang XHF, et al (2009) Tumor self-seeding by circulating cancer cells. *Cell*. 139: 1315-1326.